

# INTRODUCTION & HISTORICAL PERSPECTIVES ON DENTAL IMPLANTS

---

Before predictable and successful dental implants became available, patients who lost more than a few natural teeth often found it impossible to regain full, comfortable masticatory function and facial esthetics, no matter how much dental treatment they were willing to undergo. This was because many dental prostheses, especially the removable designs, were often little more than cumbersome, semi-esthetic, quasi-functional substitutes for missing teeth—far from ideal replacements for natural teeth. Such limitations to removable prostheses have long fed the desire for ways to reliably and firmly attach all dental prostheses to the jaws.

Dental implants have a centuries-long history; indeed there is evidence that prehistoric peoples sought this technology.<sup>1,2</sup> As dentistry progressed in the past century, experimental implant designs focused on materials and techniques that might serve as quality anchorages for conventional dental prostheses. By the mid-20th century, a number of sophisticated techniques had been developed, including *subperiosteal*, *transosteal* and *blade* implants. However none of these techniques were widely adopted because of high costs and unpredictability. Furthermore, although some of these implants functioned reasonably well for years, some began to show signs of failure shortly after insertion.<sup>3</sup> Patients often faced complex retrieval surgeries once these types of implants became intolerable.

In recent decades predictable dental implants were introduced and have revolutionized dentistry. Now, after thousands of years of trying, we have dental implants that in some circumstances (e.g., individuals with limited salivary flow who are especially prone to caries) may even be an improvement over natural teeth. This article provides an overview of contemporary concepts regarding the maintenance of modern dental implants.

## MODERN MILESTONES IN DENTAL IMPLANTOLOGY

---

In the late 1970's, a Swedish orthopedist named Per-Ingvar Brånemark introduced what he termed *osseointegrated* implants to dental practice.<sup>4</sup> The Brånemark technique utilized biocompatible titanium-alloy implants that were atraumatically inserted into the alveolar process. The devices were then recovered by soft tissue surgical flaps to isolate the implants from the oral cavity to permit several months of undisturbed healing. After three to six months, the then-osseointegrated implants were surgically uncovered and subsequently used as fixed foundations for oral prostheses. In the 1980's oral surgeons and periodontists quickly sought and received approvals from the American Dental Association to include the surgical aspects of implantology into their specialties with general dentists and prosthodontists performing most of the restorative procedures.

In spite of the quantum technological leap manifested by osseointegrated implants, it was soon apparent that the Brånemark-pioneered *two-stage* or *conventional* approach was time-consuming for many patients. Among other shortcomings, the conventional approach

necessitated a second surgical procedure as well as construction of one or more interim removable prosthodontic devices. The two-stage approach also took many months to complete and was costly. Experimentation continued and in recent years, *immediate* or *one-stage* implants have become increasingly common, especially when a patient's restorative requirements are relatively uncomplicated. Immediate implants osseointegrate while a non-occluding temporary crown is in-place in the mouth. Immediate implant patients are warned that incising, masticating or other mechanical loading of their prostheses during the healing period may increase chances for implant failure. After several months, a cosmetic and functional restoration can be fabricated to replace the temporary crown.

Despite the increasing popularity of one-stage implants, two-stage devices often remain a better choice, especially in more complex cases such as when the bone at the implant site is of sub-optimal quality, or when an implant is placed at the same time a bone graft (e.g., a maxillary sinus bone graft) is performed, or when there is no significant

upside to a one-stage approach (e.g., an implant placed to later serve as an orthodontic anchor, etc.). Furthermore, small-diameter, transitional mini-implants are sometimes used as temporary prosthetic-supporting devices while patients and dentists wait for two-stage implants to osseointegrate. These mini-implants are then removed. Alternately, mini-implants can be used longer term to support otherwise conventional removable prostheses such as dentures.

Although the overall goals of assessment, professional maintenance and home oral hygiene are the same for teeth and implants, differences in anatomy between implants and teeth are relevant to clinical assessment and maintenance procedures. For example, natural teeth have a periodontal ligament that permits small and natural movements of healthy teeth. In contrast, healthy osseointegrated implants are rigidly embedded in living bone. Another difference is that implants cannot be moved orthodontically.<sup>5</sup> As a result, implants are increasingly used as sturdy intra-oral anchorage devices to serve orthodontic ends.

# CONTEMPORARY CLINICAL CONCEPTS

## GUIDING IMPLANT MAINTENANCE

Discussed below are important features regarding the clinical assessments and professional procedures that characterize optimal implant maintenance. These considerations provide a useful intellectual foundation for each practitioner's implant maintenance protocol.

### Radiographic Assessments

Periodically, new radiographs are compared with older radiographs to look for hints of bone loss or other changes around the implants. However, unless serial radiographs are made using virtually identical exposure geometries, there is little chance that such radiographs will reliably reveal subtle changes in bone-implant relationships. Therefore, building a longitudinal series of geometrically standardized radiographs is an important aspect of optimal implant maintenance protocols. Furthermore, care should be taken to obtain radiographs that clearly depict implant threads on both mesial and distal aspects of each implant.<sup>6</sup>

In the year following implant placement and restoration a bony remodeling phenomenon termed "saucerization" is often noted around the newly restored implant and is associated with an average marginal bone loss of 0.9–1.6mm. This loss may be at least partly explained as an accommodation of the tissues to establish a "biological width" similar to that seen around natural teeth. However, following such initial phenomena, subsequent bone loss around healthy implants is minimal.<sup>8</sup>

Computer-assisted subtraction radiography is the gold standard for prompt detection of subtle changes in alveolar bone over time.<sup>9</sup> Long-cone dental radiographs made using rigid film holders are recommended. For offices not so equipped, bite wing exposures made using periapical films rotated 90 degrees (so the longer dimensions of the rectangular films extend more apically; these are sometimes called *vertical bitewings*) are generally more useful than regular bite wing radiographs or periapical radiographs that are made with minimal attempts at geometric standardization.

Practitioners should keep in mind that there are no evidence-based optimal recommendations governing the frequency of follow-up radiographs for asymptomatic patients with

dental implants. As for the natural dentition, the benefits of the information likely to be gleaned from newly exposed radiographs need to be weighed against the costs and the potential harm associated with exposing patients to (the small doses of) ionizing radiation inherent in modern dental radiography. Consistent with American Dental Association and FDA guidelines<sup>10</sup> governing indications for dental radiography, it is sensible that the frequency of re-assessment radiographs would decrease over time for implant patients whose status remains stable.

### Visual Assessments

Implants and attached crowns or other prostheses should be inspected for damaged components. Damaged implant or other prosthetic components often necessitate immediate attention by the dentist.

In otherwise healthy patients, the appearance of purulent (pus-producing), swollen and/or reddened gingiva (or oral mucosa) or bleeding on gentle probing adjacent to an implant abutment are typical indicators of inflammation, which in turn, suggests some sort of pathology. Most often this *peri-implant mucositis* is the result of persistent bacterial biofilm adhering to an implant. If the infection is not arrested it may progress apically causing proximate bone loss (termed *peri-implantitis*) and may even culminate in implant loss. Calculus that adheres to implant fixtures or prostheses may aggravate inflammation by serving as a reservoir for infecting bacteria.<sup>11</sup>

Moreover, in recent years, it has become increasingly clear that some individuals have what appears to be a genetic predilection to an overly exuberant inflammatory response.<sup>12</sup> Therefore, it should come as no surprise that patients with a history of periodontitis are more prone to peri-implant inflammation and its associated effects.<sup>13</sup>

Finally, another plausible inflammatory etiology needs to be considered. Allergic reactions to certain components of dental prostheses, including titanium implant materials are rare:<sup>14</sup> however allergies should be considered as a possibility underlying otherwise unexplained local or systemic reactions. Another uncommon clinical presentation is the presence of a fistula that may indicate a fractured implant.<sup>15</sup>

### Mobility Assessments

Implant mobility should be assessed. This can be accomplished using two dental instrument handles and trying to rock the implant, the same as is done for natural teeth.

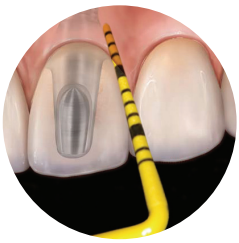
Unlike natural teeth where a subtle amount of mobility is normal, any implant mobility (or pain induced by chewing, incising or when otherwise mechanically loaded) may be a sign of a failing implant.<sup>16</sup> A key exception to this rule is when an internal screw or other fastener used to attach a restorative component to the osseointegrated implant component loosens or shears. Often patients will notice such occurrences immediately and if the prostheses remain attached, patients may report that their teeth suddenly "stopped coming together" properly. When internal implant attachments fail, patients can often remember precise details regarding when and where the symptoms first arose.

### Probing Assessments

The hemidesmosomal attachment of oral epithelium to implant or natural tooth surfaces is similar if not identical.<sup>17</sup> However, unlike with natural teeth, collagen fibers in the subjacent connective tissue do not embed into the implants, rather they run parallel to the implant surfaces. This anatomical arrangement led to past recommendations not to probe apparently healthy implants because it was thought that periodontal probe penetration into these tissues could occur easily and might abet the induction of bacteria and infection.<sup>18</sup> However in recent years, despite even recent recommendations to the contrary<sup>19</sup>, the consensus view is now that routine gentle probing of osseointegrated implants is indicated.<sup>20</sup>

Dimensional data such as probing depths, along with sites that bleed or suppurate on probing, should be recorded as a basis for immediate treatment decisions and for comparison with previous and subsequent examination data in the context of longer-term assessments.<sup>21</sup> It may be worth recalling that typical probing depths around tis-





Colorvue probe assessing peri-implant sulcus.  
Photo Credit: Courtesy of Montage Media

sue-healthy implants tend to be slightly greater than the probing depths typical of healthy gingivae proximate to natural teeth.<sup>22</sup> Typical stainless steel periodontal probes are not recommended for use around implants because

they may scratch softer implant surfaces. Scratches or other roughness may facilitate the subsequent attachment of dental plaque and calculus to the area.<sup>23</sup> Plastic periodontal probes such as Hu-Friedy's Colorvue® Probes are appropriate.

The same gentle-but-thorough probing technique used for natural teeth is recommended for implants. Anatomic measurements such as probing depths as well as responses to probing by adjacent gingiva (e.g., bleeding on probing) should be recorded at every implant maintenance appointment. Some practitioners record probing depths at only four-points (i.e., mesial, distal, facial and lingual aspects) around each implant instead of the six-point measures commonly recorded for natural teeth. However, regarding both natural teeth and implants, what's important is that the entire circumferential extent of the crevices be assessed and that pocket depth measurements are made and recorded in a consistent manner at each maintenance appointment so that the measurements can be compared over time. Small changes ( $\leq 2$ mm) in probing depths observed over brief periods may reflect the probing variables sometimes seen around periodontally stable natural teeth that may have varying degrees of resistance to the probe.<sup>24</sup> On the one hand, small decreases in probing depths around teeth or implants may be the result of improved personal oral hygiene. On the other hand, increases in probing depths may indicate new or more florid peri-implant mucocitis (analogous to gingivitis) or progressing peri-implantitis (analogous to periodontitis).

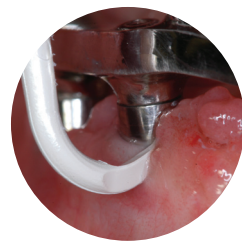
Bleeding on gentle probing is indicative of the presence of inflamed tissue.<sup>25</sup> Such observations should be considered in the same context as described above under the **Visual Assessment** subheading. The consistent absence of bleeding on probing around natural teeth is a desirable clinical waypoint because this situation has been linked to long-term periodontal health (especially in

non-smokers).<sup>26</sup> It is therefore reasonable to assume a similar prognostic interpretation for implants.

For those practitioners in the habit of utilizing pocket probing depths as a basis to compute clinical attachment levels around natural teeth, the lack of a cemento-enamel junction on implants makes serial attachment level assessments more difficult.

### Implant Surface Debridement

At every maintenance visit, implants should be completely debrided, including removal of all plaque/biofilm and calculus. In general, the maintenance mechanics for implants and natural teeth are similar with a few notable exceptions. Unlike natural teeth where sharp, and hard-metallic instruments are used to remove calculus and to de-plaque softer dentinal and cemental root surfaces, such instruments are not recommended for implant debridement. Instead, instruments softer than titanium are used for debridement to avoid scratching the implants. Power scalers may be used but also only with implant and abutment-safe tips.<sup>27</sup> Currettes designed for use on implants, such as Hu-Friedy's ImplanCare™ Implant Scalars



ImplanCare scaler debriding the abutment surface of #27  
Photo Credit: Courtesy of Denise Lirette, RDH, BS

are appropriate examples. There is limited evidence that frequent rubber cup polishing results in a smoother implant surface.<sup>23</sup> If polishing is to be performed, a non-abrasive polishing paste is recommended.<sup>28</sup>

### Personal Oral Hygiene Recommendations

Patients should be encouraged to thoroughly and circumferentially de-plaque implant fixtures at least once daily, just like natural teeth. (Some patients may benefit from more frequent self-care.) If a patient's implants support a removable prosthesis, the prosthesis should be removed (and cleaned according to the clinician's instructions) and implant personal hygiene performed with the denture out of the mouth. Furthermore, just as for removable conventional prostheses, implant-supported removable prostheses should be removed before sleeping.

Standard toothbrushes or powered toothbrushes may be used. Dental floss can be wrapped around the implants and be made to extend slightly subgingivally. Indeed, some flossing products are designed specifically for implant care. At appropriate sites, manual interproximal brushing using specially designed metal-free interproximal brushes can also be very useful. Dipping any of these devices into the oral disinfectant 0.12% chlorhexidine gluconate before use may increase personal hygiene effectiveness.

### Modulated Professional Maintenance Intervals

A typical initial maintenance recare interval for patients with implants is every three months. However, similar to how patients with natural teeth are managed, recare intervals should be adjusted based on the results of clinical re-assessments. In other words, patients who maintain soft tissues around their implants inflammation-free should be considered for lengthened recare intervals. However, patients who exhibit clinical signs suggesting peri-implant inflammation will likely benefit from more frequent maintenance care.

### Refractory Inflammation

When inflammation persists, it's necessary to confirm that prior debridement was thorough, and if not, re-treat. Practitioners should know that in recent years increasing research on inflammation suggests that some individuals with periodontitis appear to be hyper-responders to infection.<sup>29, 30</sup> In light of the fact that inflammation itself is often responsible for a significant percentage of the tissue destruction associated with periodontitis, it's reasonable to assume the same problems may manifest around implants in such patients.

Therefore, in the uncommon circumstances when inflammation persists proximate to an implant despite meticulous debridement, good self-care and frequent professional care, prescription therapeutic adjuncts can be useful. These include:

- 20mg twice-daily doxycycline hyclate tablets (e.g., Periostat®, Galderma Labs, Fort Worth TX) that down-regulate the patient's inflammatory response. (Generic versions of this drug are generally available at local pharmacies.)
- Locally applied antimicrobials such as sustained, slow-release and biodegradable minocycline microspheres (e.g., Arestin®, OraPharma Inc., Warminster, PA).

# TODAY AND THE FUTURE

In less than just a few decades, dental implants have moved from the fringes of dentistry to the mainstream. Indeed, implants are now utilized for purposes not foreseen even a decade ago. As implants become more common, thoughtful approaches to implant maintenance are becoming increasingly important in modern dental practice. Ideal implant maintenance should be customized to individual patient's needs.

As time passes, we will learn more about the natural history of osseointegrated oral implants. Maintenance tactics will evolve accordingly.

## CITATIONS

- <sup>1</sup> Bobbio A. Maya, the first authentic alloplastic, endosseous dental implant. A refinement of a priority. *Rev Assoc Paul Cir Dent.* 1973;27:27–36.
- <sup>2</sup> Tapia JL, Suresh L, Plata M, Aquirre A. Ancient esthetic dentistry in Mesoamerica. *Alpha Omegan.* 2002; 95:21–4.
- <sup>3</sup> James RA. Subperiosteal implant design based on peri-implant tissue behavior. *N Y J Dent.* 1983;53:407–414.
- <sup>4</sup> Branemark PI, Hansson BO, Adell R, et al. Osseointegrated implants in the treatment of the edentulous jaw. Experience from a 10-year period. *Scand J Plast Reconstr Surg Suppl.* 1977;16:1–132.
- <sup>5</sup> Weitz ML, Mukamal EO, Jurim A. An orthodontic device to capitalize on the rigid fixation of osseointegrated implants. *Int J Periodontics Restorative Dent.* 1998; 18:240–47.
- <sup>6</sup> Misch C. Dental Implant Prosthetics. Saint Louis: CV Mosby Co.; 2005:145–153.
- <sup>7</sup> Gargiulo A, Wentz F, Orban b. Dimensions and relations of the dentogingival junction in humans. *J Periodontol.* 1961;32:261–268.
- <sup>8</sup> Oh TJ, Yoon J, Misch CE, et al. The causes of early implant bone loss: myth or science? *J Periodontol.* 2002;73:322–333.
- <sup>9</sup> Rethman, M, Ruttiman U, O'Neal R, et al. Subtraction radiography for the diagnosis of bone lesions in dogs; *J Periodontol.* 1985;56:324–329.
- <sup>10</sup> American Dental Association. Guidelines for prescribing dental radiographs, 2004. Available at: [http://gsa.ada.org/search?entqr=0&access=p&output=xml\\_no\\_dtd&sort=date%3AD%3AL%3Ad1&ie=UTF8&btnG=Search&btnG.y=11&client=ADAorg\\_FrontEnd&q=radiographic+guidelines&btnG.x=24&ud=1&site=ADAorg\\_Collection&oe=UTF8&proxystylesheet=ADAorg\\_FrontEnd&ip=72.234.165.218&proxyreload=1&filter=0](http://gsa.ada.org/search?entqr=0&access=p&output=xml_no_dtd&sort=date%3AD%3AL%3Ad1&ie=UTF8&btnG=Search&btnG.y=11&client=ADAorg_FrontEnd&q=radiographic+guidelines&btnG.x=24&ud=1&site=ADAorg_Collection&oe=UTF8&proxystylesheet=ADAorg_FrontEnd&ip=72.234.165.218&proxyreload=1&filter=0) (Accessed Feb 12, 2009)
- <sup>11</sup> Patters MR, Landesberg RL, Johansson LA, et al. Bacteroides gingivalis antigens and bone resorbing activity in root surface fractions of periodontally involved teeth. *J Periodontol Res.* 1982;17:122–130.
- <sup>12</sup> Kornman KS. Mapping the pathogenesis of periodontitis: a new look. *J Periodontol.* 2008;79:1560–68.
- <sup>13</sup> Ong, C, Ivanovski S, Needleman I, et al. Systematic review of implant outcomes in treated periodontitis subjects. *J Clin Periodontol.* 2008; 35:438–462.
- <sup>14</sup> Sicilia A, Cuesta S, Coma G, et al. Titanium allergy in dental implant patients; a clinical study on 1500 consecutive patients. *Clin Oral Implants Res.* 2008; 19:823–835.
- <sup>15</sup> Silverstein LH, Meffert RM, Jeffcoat M, et al. *Clark's Clinical Dentistry. Vol 5.* Saint Louis: Mosby Year Book; 1998: chap 62.
- <sup>16</sup> Cochran D. Implant therapy I. *Ann Periodontol.* 1996;1:707–791.
- <sup>17</sup> James RA, Schultz RL. Hemidesmosomes and the adhesion of junctional epithelial cells to metal implants—a preliminary report. *Oral Implantol.* 1974;4:294–302.
- <sup>18</sup> Lang NP, Wetzel AC, Stich H, et al. Histologic probe penetration in healthy and inflamed peri-implant tissues. *Clin Oral Implants Res.* 1994;5:191–201.
- <sup>19</sup> Silverstein LH, Kurtzman GM. Oral hygiene and the maintenance of dental implants. *Dent Today.* 2006;25:70–75.
- <sup>20</sup> Heitz-Mayfield LJ. 6th European Workshop on Periodontology. *J Clin Periodontol.* 2008 Sep;35(8 Suppl):292–304.
- <sup>21</sup> Quirynen M, van Steenberghe D, Jacobs R, et al. The reliability of pocket probing around screw-type implants. *Clin Oral Implants Res.* 1991;2:186–192.
- <sup>22</sup> van Steenberghe D, Klinge B, Linden U, et al. Periodontal indices around natural and titanium abutments: a longitudinal multicenter study. *J Periodontol.* 1993;64:538–541.
- <sup>23</sup> Speelman JA, Collaert B, Klinge B. Evaluation of different methods to clean titanium abutments. A scanning electron microscopic study. *Clin Oral Implants Res.* 1992;3:120–127.
- <sup>24</sup> Garnick, JJ, Silverstein L. Periodontal probing: probe tip diameter. *J Periodontol.* 2000;71:96–103.
- <sup>25</sup> Greenstein G, Caton J, Polson AM. Histologic characteristics associated with bleeding after probing and visual signs of inflammation. *J Periodontol.* 1981;52:420–425.
- <sup>26</sup> Genjo RJ, Jeffcoat M, Caton J Jr, et al. Consensus report. Periodontal diseases: Epidemiology and diagnosis. *Ann Periodontol.* 1996;1:216–222.
- <sup>27</sup> Gantes BG, Nilveus R. The effects of different hygiene instruments on titanium surfaces: SEM observations. *Int J Periodontics Restorative Dent.* 1991;11:225–239.
- <sup>28</sup> Rapley JW, Swan RH, Hallmon WW, et al. The surface characteristics produced by various oral hygiene instruments and materials on titanium implant abutments. *Int J Oral Maxillofac Implants.* 1990;5:47–52.
- <sup>29</sup> Kornman KS. Mapping the pathogenesis of periodontitis: a new look. *J Periodontol.* 2008;79:1560–68.
- <sup>30</sup> Offenbacher S, Barros SP, Beck JD. Rethinking periodontal inflammation. *J Periodontol.* 2008; 79:1577–84.

**About this publication:** This white paper was commissioned by Hu-Friedy and authored by Dr. Michael P. Rethman. The opinions expressed herein are the Dr. Rethman's alone and not necessarily those of the Hu-Friedy Corporation.

**About the author:** Dr. Michael P. Rethman is a Honolulu periodontist, adjunct assistant professor of Periodontology at The Ohio State University College of Dentistry and adjunct assistant professor of Periodontology at the Baltimore College of Dental Surgery, University of Maryland. He is also a past-President of the American Academy of Periodontology, a former Director of the U.S. Army Institute of Dental Research and chairs the American Dental Association's Council on Scientific Affairs. Dr. Rethman lectures and writes on a variety of topics in dentistry.

