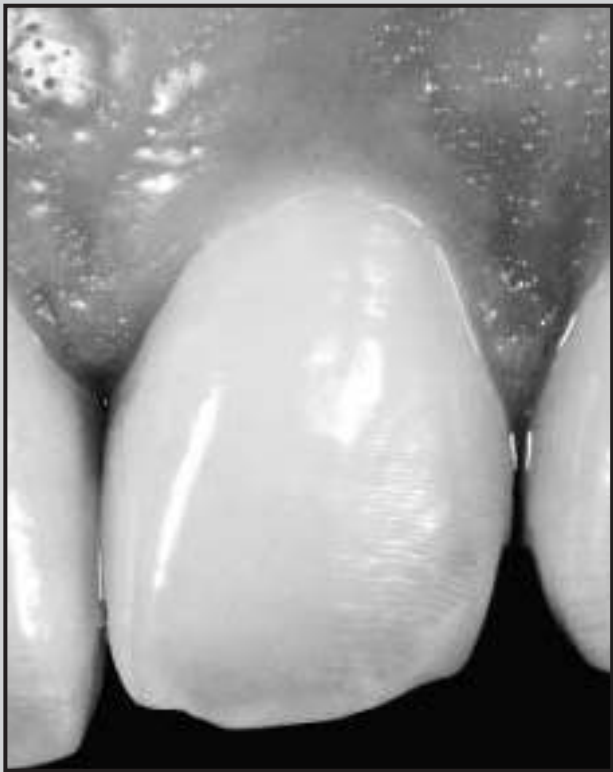
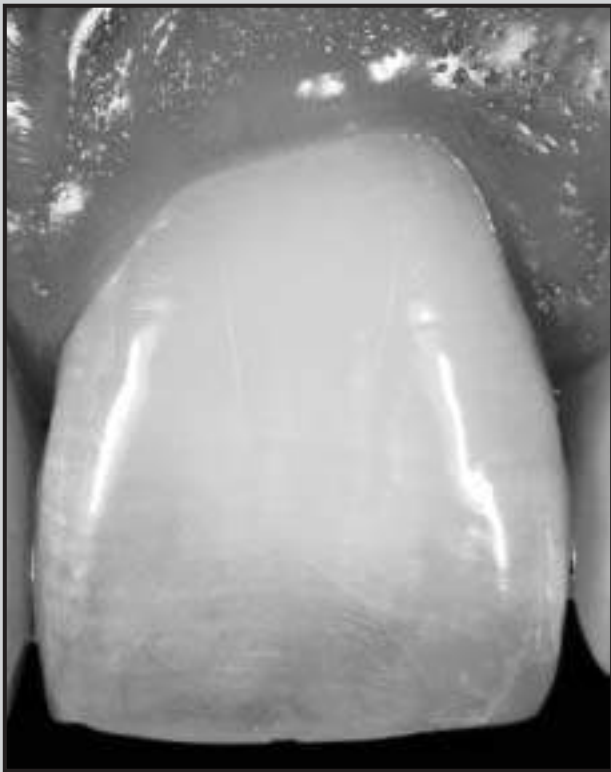
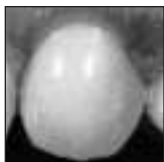Papilla Proportions in the Maxillary Anterior Dentition



Stephen J. Chu, DMD, MSD, CDT*

Dennis P. Tarnow, DDS**

Jocelyn H.-P. Tan, DDS***

Christian F. J. Stappert, DDS, MS, PhD****

Two hundred forty interdental papilla sites in 20 healthy patients were investigated. Interdental papilla heights of maxillary anterior teeth were measured from the gingival zenith, along with clinical crown lengths. Percentages of papilla height to crown length were computed and defined as papilla proportion, mesial papilla proportion (MPP), and distal papilla proportion (DPP). Mean interdental papilla heights of maxillary anterior teeth were 4 mm mesially and 4.1 mm distally. Mean MPP was 42% (n = 120), and mean DPP was 43% (n = 120). No significant differences were found between MPP and DPP for maxillary incisors ($P \geq .5$). Canines demonstrated a trend toward increased distal papilla heights. Papilla proportions were approximately 40% for all tooth groups. A more apical position of distal papilla heights from anterior to posterior teeth, mentioned in the literature, was not confirmed by the present data. (Int J Periodontics Restorative Dent 2009;29:385–393.)

*Clinical Associate Professor, Department of Periodontology and Implant Dentistry, New York University College of Dentistry, New York, New York.

**Professor and Chairman, Department of Periodontology and Implant Dentistry, New York University College of Dentistry, New York, New York.

***General Practice Resident, New York Hospital Queens, Flushing, New York.

****Assistant Professor, Department of Periodontology and Implant Dentistry, Department of Biomaterials and Biomimetics, New York University College of Dentistry, New York, New York; Associate Professor, Department of Prosthodontics, Albert-Ludwigs-University, Faculty of Dentistry, Freiburg, Germany.

Correspondence to: Dr Stephen J. Chu, Department of Periodontology and Implant Dentistry, New York University College of Dentistry, Arnold and Marie Schwartz Hall of Dental Sciences, 345 East 24th Street, New York, NY 10010; fax: +1-212-995-4081; email: schudmd@aol.com.

An interdisciplinary team approach to multidisciplinary therapies in esthetic restorative treatment has become commonplace in the dental profession. The perception of dental esthetics, however, varies significantly among dental professionals, although substantial efforts have been made to establish common standards. Several textbooks have sought to help guide clinicians in optimizing esthetic results. Rufenacht,^{1,2} for example, discussed the fundamentals of esthetics and described procedures for integrating dental restorations into the individual facial composition with respect to biologic and functional requirements, not merely esthetics. Goldstein³ attempted to establish principles to help practitioners achieve esthetic results and develop a rationale for esthetic dental treatment. Fradeani⁴ described a systematic approach to esthetic analysis, evaluation, and treatment based on general principles and illustrated that the height of the interdental papillae decreased from anterior to posterior teeth. Despite these efforts, there is still little consistency among clinicians' perspectives of what constitutes an esthetic smile.^{5–11} With an increased

awareness and understanding of esthetic dentistry, patients today require natural-looking teeth and gingival architecture in the esthetic zone.

It is the interdental appearance of the papillae in an apicocoronal location that is critical during smiling that results in positive gingival architecture esthetics,^{12,13} although the supra-coronal tissues might not always be visible in patients with a low smile line. LaVacca et al¹⁴ conducted a study to evaluate the impact of symmetric alterations in interdental papilla length on esthetic perceptions. The authors reviewed the importance of interdental papilla location for optimal esthetics and its assessment by dental professionals and patients. Although dental specialists were more consistent than patients in their evaluation of the impact of interdental papilla length on the perception of esthetics, this study demonstrated that there is still a need to enhance communication and standardize evaluation among dental specialists to achieve consistent treatment planning goals.

There is no universal guideline for clinicians to follow in creating greater conformity and a predictable esthetic smile, including ideal papilla heights. It may be possible to mathematically quantify certain esthetic components to establish a standard that is satisfying to both patients and clinicians.

Chu¹⁵ suggested that a mathematical correlation exists between the clinical crown widths of maxillary anterior teeth. The investigation unveiled that variations of tooth width existed more frequently (~68%) than mean averages (~32%). It was concluded that individual clinical crown size must

be identified prior to treatment to promote a more esthetic result. Accordingly, it may be feasible to quantify the heights of the interdental papillae of the maxillary anterior teeth as measured from the level of the zenith of the labial free gingival margin (gingival zenith).

Several investigators have attempted to establish guidelines for proper papillae form to enhance denture esthetics, optimize soft tissue position, improve surgical and nonsurgical techniques to treat soft tissue deformities, and to better manage interproximal spaces following tooth extraction or implant placement.¹⁶⁻²⁰ Spear¹⁷ presented a clinical technique for maintaining papilla height and form following anterior tooth removal. He believed that the presence of adjacent tooth attachment and the size of the gingival embrasure formed by these teeth were responsible for papilla presence and height. Tarnow et al²¹ examined the distance from the base of the contact area to the crest of bone in 288 sites and determined that, at 5 mm, 6 mm, and 7 mm, the papilla was present 98%, 56%, and 27% of the time, respectively. Cho et al²² and Martegani et al²³ found that the interradicular distance and the distance between the contact point and the alveolar crest have independent and combined effects on the presence or absence of the interdental papilla. Based on this information, clinicians are able to influence and maintain papilla development more effectively, but they must rely on the alveolar crest as a reference point.

The height of the interdental papillae between the maxillary anterior

teeth, with reference to the crest of the gingival zenith, remains undefined. To date, no investigation has determined what the representative value of the anatomical location of the interdental papilla should be from the gingival zenith. There are currently no studies designed to evaluate or quantify this location. Therefore, the purpose of this pilot study was to quantify the interdental papilla location mathematically as a percentage ratio of clinical crown length, thereby establishing a useful parameter for treatment.

Method and materials

A sample population of 20 patients (13 women, 7 men) was studied. The patients, who ranged in age from 20 to 47 years (mean, 27.7 years), were in good systemic health. The sample population were included on the basis of nonrestored maxillary anterior teeth, no loss of interdental papillae, no anterior crowding or spacing, no incisal attrition, no periodontal disease, and no gingival recession (Fig 1).

Alginate impressions of the study subjects were made using irreversible hydrocolloid impression material (Jeltrate, Dentsply Caulk) and immediately poured with stone (Resin Rock, Whip Mix Corp). A digital caliper with a lighted display (SAE/Metric) was used to measure the 240 papilla sites of the anterior maxillary teeth, from canine to canine (Avenger Measuring Tools). Each cast was measured by one operator using 2.5× optical loupes. Control measurements were performed by a second investigator. The caliper was calibrated prior to each measurement.

Fig 1 Healthy patient with sound maxillary anterior dentition and interdental papillae between central and lateral incisors as well as canines.

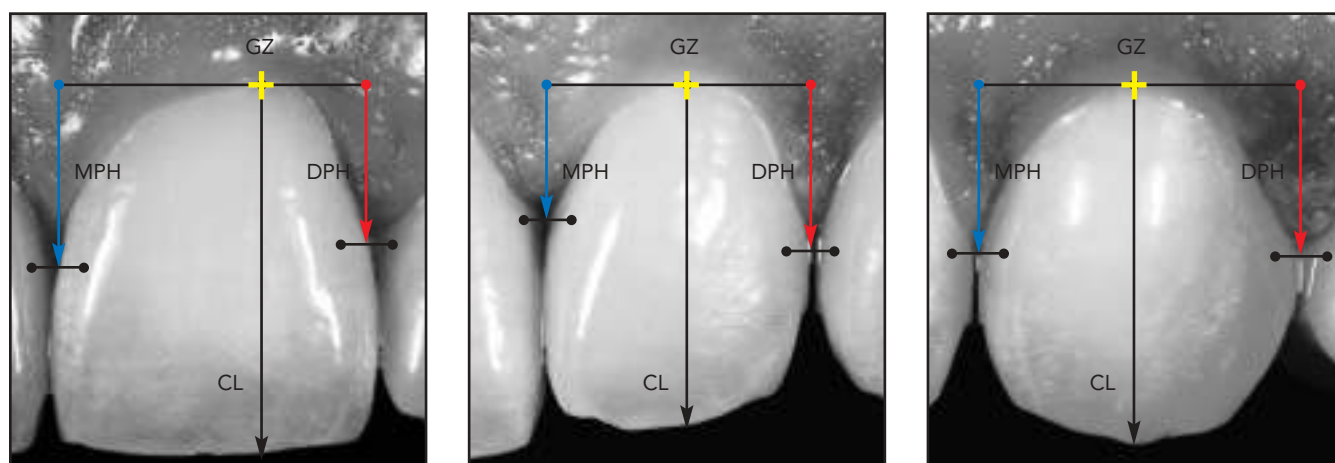
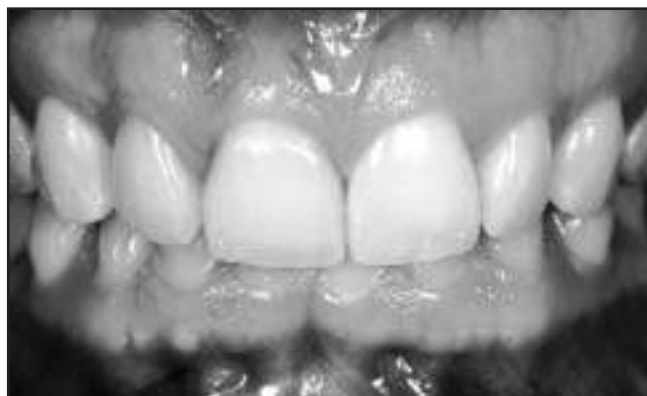

Fig 2 Height measurements were made from the level of the gingival zenith (GZ) to the tip of the mesial papilla (MPH) and distal papilla (DPH) for (left) the central incisor, (center) the lateral incisor, and (right) the canine, as well as for clinical crown length (CL).

The mesial and distal interdental papilla heights in the maxillary anterior dentition, including the central incisors (CI), lateral incisors (LI), and canines (CA), were measured from the level of the gingival zenith of the corresponding tooth to the tip of the papilla ($n = 240$) (Fig 2). Additionally, the lengths and widths of clinical crowns were recorded for each tooth group: CI, LI, and CA ($n = 120$). Each papilla height measurement was divided by the clin-

ical crown length of the corresponding tooth. Therefore a percentage ratio was calculated of the papilla height related to the clinical crown length. The percentage ratio accounted for variations in crown lengths and papilla heights and was not predicated upon absolute values.

The following mathematical equation was used to calculate a percentage ratio, termed papilla proportion (PP): $PP = \text{papilla height}/\text{crown length}$

$\times 100\%$. Mesial papilla proportions (MPP) and distal papilla proportions (DPP) were calculated separately: $MPP = \text{mesial papilla height}/\text{crown length} \times 100\%$, and $DPP = \text{distal papilla height}/\text{crown length} \times 100\%$.

This study was conducted according to the Declaration of Helsinki for clinical investigations. Statistical analysis was performed by independent-sample t tests and binomial tests ($\alpha = .05$).

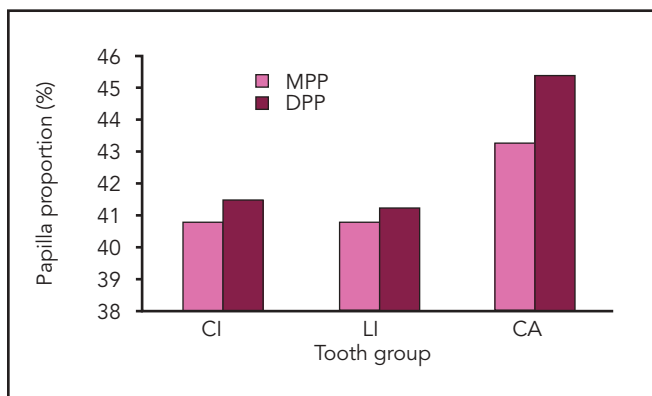


Fig 3 Percentage ratio of papilla height to crown length sorted by tooth group and divided into mesial papilla proportion (MPP) and distal papilla proportion (DPP). CI = central incisors; LI = lateral incisors; CA = canines.

Table 1 Absolute values of papilla heights (in mm) sorted by tooth position and divided into mesial (MPH) and distal (DPH) groups

Tooth position	n	Group	Mean \pm SD	Min	Max
Right CA	20	MPH	4.2 \pm 0.87	2.9	6.2
Right CA	20	DPH	4.5 \pm 0.74	3.3	6.0
Right LI	20	MPH	3.5 \pm 0.69	2.4	5.0
Right LI	20	DPH	3.6 \pm 0.98	2.0	5.1
Right CI	20	MPH	4.3 \pm 0.71	3.1	5.8
Right CI	20	DPH	4.3 \pm 0.62	3.4	5.8
Left CI	20	MPH	4.2 \pm 0.82	2.9	5.7
Left CI	20	DPH	4.2 \pm 0.60	3.3	5.6
Left LI	20	MPH	3.8 \pm 0.78	2.4	5.7
Left LI	20	DPH	3.8 \pm 0.83	2.4	5.7
Left CA	20	MPH	4.3 \pm 0.33	3.7	5.0
Left CA	20	DPH	4.4 \pm 0.73	3.3	5.7

CI = central incisor; LI = lateral incisor; CA = canine.

Results

The mean absolute values (\pm SDs) for the interdental papilla heights of maxillary anterior teeth measured from the level of the gingival zenith were 4.0 ± 0.8 mm mesially and 4.1 ± 0.8 mm distally. The mean absolute interdental papilla heights (\pm SDs) by tooth of CI, LI, and CA were 4.3 ± 0.7 mm, 3.7 ± 0.8 mm, and 4.4 ± 0.7 mm, respectively. Taking into account all measured

sites, the mean MPP (\pm SD) was $42\% \pm 6\%$ ($n = 120$), and the mean DPP was $43\% \pm 7\%$ ($n = 120$). The measurements demonstrated a normal distribution, which accounted for about 68% of the data for one standard deviation from the mean (\pm SD). The MPP for the CI, LI, and CA were 40.8%, 40.8%, and 43.3%, respectively. The DPP of the CI, LI, and CA were 41.5%, 41.1%, and 45.4%, respectively (Fig 3). Table 1 demonstrates the absolute

Fig 4 Absolute values of papilla heights (lengths) by tooth position and divided into mesial papilla height (MPH) and distal papilla height (DPH). FDI tooth-numbering system used.

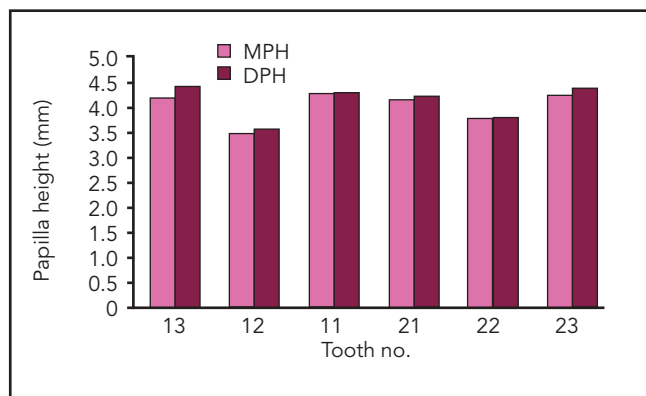


Table 2 Clinical crown lengths (CL) and widths (CW) (in mm) measured in the maxillary anterior dentition, sorted by tooth position

Tooth position	n	Group	Mean \pm SD	Min	Max
Right CA	20	CL	9.7 \pm 0.9	8.3	11.1
Right CA	20	CW	7.8 \pm 0.62	6.8	9.4
Right LI	20	CL	8.8 \pm 0.9	7.2	10.5
Right LI	20	CW	6.8 \pm 0.68	5.3	8.2
Right CI	20	CL	10.3 \pm 0.8	8.7	11.9
Right CI	20	CW	8.8 \pm 0.55	7.7	9.6
Left CI	20	CL	10.3 \pm 0.71	8.9	11.8
Left CI	20	CW	8.8 \pm 0.56	7.7	9.7
Left LI	20	CL	9.0 \pm 0.83	6.8	10.4
Left LI	20	CW	6.9 \pm 0.68	5.6	8.2
Left CA	20	CL	9.9 \pm 0.73	8.8	11.4
Left CA	20	CW	7.9 \pm 0.49	6.9	8.8

CI = central incisor; LI = lateral incisor; CA = canine.

values of interdental papilla heights sorted by tooth position (Fig 4). Table 2 shows the descriptive data of clinical crown lengths and crown widths accordingly. MPP and DPP values are given in Table 3 (Fig 5). No significant differences were found between MPP and DPP for the maxillary incisors (groups CI and LI) ($P \geq .51$). The canines demonstrated a trend toward greater distal papilla lengths and higher DPP; this difference was significant for the

right canine ($P = .04$) and was not significant for the left canine ($P = .24$). The mean difference between MPP and DPP for all values ($n = 240$) was 1%, but not significant ($P = .06$). The mean difference between distal and mesial measures aggregated over all teeth was 0.1 mm ($P = .054$). Because of the canine measures, the difference was nearly significant.

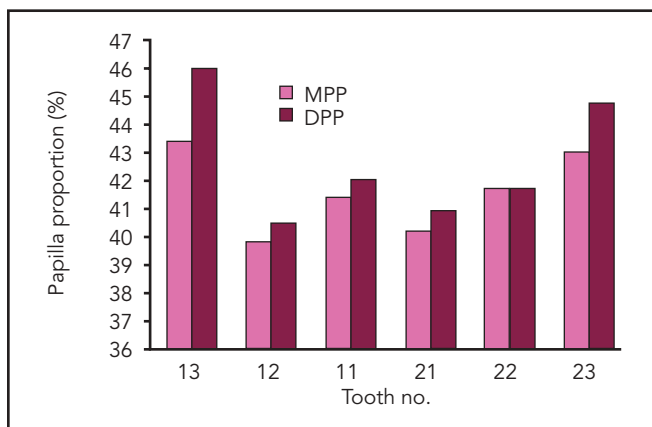


Fig 5 Percentage ratio of papilla height to crown length sorted by tooth position and divided in mesial papilla proportion (MPP) and distal papilla proportion (DPP). FDI tooth-numbering system used.

Table 3 Percentage ratio of papilla height to crown length sorted by tooth position and divided into mesial (MPP) and distal (DPP) groups

Tooth position	n	Group	Mean \pm SD	Min	Max
Right CA	20	MPP	43 \pm 7	31	56
Right CA	20	DPP	46 \pm 6	34	55
Right LI	20	MPP	40 \pm 6	29	48
Right LI	20	DPP	41 \pm 8	27	55
Right CI	20	MPP	41 \pm 5	32	49
Right CI	20	DPP	42 \pm 5	32	53
Left CI	20	MPP	40 \pm 6	29	53
Left CI	20	DPP	41 \pm 5	30	50
Left LI	20	MPP	42 \pm 7	25	57
Left LI	20	DPP	42 \pm 8	25	58
Left CA	20	MPP	43 \pm 4	35	50
Left CA	20	DPP	45 \pm 7	30	58

CI = central incisor; LI = lateral incisor; CA = canine.

Discussion

The goal of this study was to determine a representative value for interdental papilla height of the maxillary anterior dentition as a percentage ratio of clinical crown length, as measured from the level of the gingival zenith. Ideally, this figure would be relevant and clinically applicable for practitioners striving to achieve a more esthetic smile.

Furthermore, this value could be helpful for periodontists and implant dentists in validating and planning surgeries concerning desired vertical soft tissue height in the esthetic zone.²⁰ The mean absolute interdental papilla heights by tooth of CI, LI, and CA were 4.3 mm, 3.7 mm, and 4.4 mm, respectively. Values of interdental papilla heights in the maxillary anterior dentition have been mentioned in the

literature. Kois²⁴ measured interdental papilla heights from the free gingival margin to the osseous crest with a periodontal probe. Mesial sites at the maxillary right central incisor in 100 healthy patients were observed. Kois²⁴ reported a range of 3 to 4.5 mm interproximal depth. No additional anterior teeth or interdental sites were measured.

Becker et al²⁵ evaluated human skulls and classified them into flat, scalloped, and pronounced scalloped anatomical profiles according to alveolar bone anatomy. The mean distance from the height of the interdental bone to the buccal alveolar crest was statistically significantly different when the groups were compared (flat 2.1 mm, scalloped 2.8 mm, and pronounced 4.1 mm). Spear¹⁷ concluded that the osseous scallop from facial to interproximal averages 3 mm in height. Taking an average of 3 mm dentogingival complex height into account, Spear concluded that the facial free gingival margin height equals the interproximal aspect of bone in a healthy patient. Therefore, he estimated that the average maxillary interproximal papilla height would be 4.5 to 5.5 mm for central incisors (Spear referred to Kois²⁴), also when measured from the facial zenith of the free gingival margin. Spear did not provide control measurements for this estimate but cited a study of van der Velden,²⁶ who reported interdental tissue recovery after surgical treatment of 4.3 mm on average and a mean sulcus depth of 2.2 mm. An estimate of interdental papilla height of 4.5 mm correlates with the current statistical findings for central incisors and canines, with mean

crown lengths of 10.3 mm and 9.8 mm, respectively. Lateral incisors demonstrated a smaller mean value of interdental papilla height of 3.7 mm, with a mean crown length of 8.9 mm. The investigation of Tarnow and coworkers²¹ on the influence of the contact point position on the presence or absence of the interproximal dental papilla was reevaluated by Cho et al.²² The authors measured anterior and posterior interdental sites. The data confirmed the findings of Tarnow et al²¹ that the number of papillae that filled the interproximal space decreased with increasing distance from the contact point to the alveolar crest. The authors reported that the interdental papillae were present in 89.7% of sites when the distance from the contact point to the alveolar crest was 4 mm, 58.5% of sites when the distance was 5 mm, 35.2% of sites when the distance was 6 mm, and fewer than 7.5% of sites when the distance was > 7 mm. Their results also suggested that an increasing interproximal distance between the tooth roots has a significant decreasing influence on the papilla presence. Unfortunately, the study did not provide absolute interdental papilla height values of the anterior maxillary dentition for comparison.

It is important to note that mean absolute values are important findings but do not account for individual variations in crown lengths and papilla heights. For esthetic anterior restorations, papilla heights must be proportional to clinical crown lengths. Hence, mathematical equations were presented as proportion calculations, which accounts for variability in clinical crown length. The average MPP and

DPP of the CI, LI, and CA measured were 41% and 42%, 41% and 41%, and 43% and 45%, respectively. These proportion ratios would account for variations in clinical crown length and would not be dependent upon absolute tooth measurement values. Although 240 papilla sites were measured, the number of investigated patients ($n = 20$) might be a short coming of the present study. However, the calculated standard deviation of all PP measurements ($n = 240$) was less than 7%, which equaled an esthetic natural appearance of the papilla within a 36% to 49% PP range. The given range of data (min/max) represents isolated measurements located at the extended tails of the bell curve. Further studies are needed to verify these results.

The perception of beauty is very subjective and often influenced by societal and/or geographic factors. Nevertheless, this study may be used as a pilot reference, providing some guidance for clinicians. By mathematically quantifying the papilla length from the gingival zenith, dental professionals can communicate more efficiently and with a more uniform treatment goal. As a result, a closer-to-ideal spatial relationship between teeth and their respective papillae can be established to achieve optimized esthetics.

Conclusions

The percentage ratios of papilla heights and crown lengths demonstrated an almost equivalent papilla proportion for all tested tooth groups of approximately 40%. There were no

clinically relevant differences in mesial versus distal papilla heights in the anterior maxillary dentition. A more apical position of distal papilla heights from anterior to posterior teeth as mentioned in the literature was not confirmed by the present data.

Acknowledgments

The authors are grateful to Malvin Janal, PhD, Department of Psychiatry, New Jersey Medical School, for carrying out the data analyses. They are also thankful to Andrew Pacellini, DDS, Prosthodontic Resident, New York Hospital Queens, Flushing, New York, for his support during data collection.

References

1. Rufenacht CR. *Fundamentals of Esthetics*. Chicago: Quintessence, 1990.
2. Rufenacht CR. *Principles of Esthetic Integration*. Chicago: Quintessence, 2000.
3. Goldstein RE. *Esthetics in Dentistry*. Hamilton, Ontario: BC Decker, 1998.
4. Fradeani M. *Esthetic Rehabilitation in Fixed Prosthodontics. Esthetic Analysis: A Systematic Approach to Prosthetic Treatment*. Chicago: Quintessence, 2004.
5. Rosenstiel SF, Ward DH, Rashid RG. Dentists' preferences of anterior tooth proportion—A web-based study. *J Prosthodont* 2000;9:123–136.
6. Snow SR. Esthetic smile analysis of maxillary anterior tooth width: The golden percentage. *J Esthet Dent* 1999;11:177–184.
7. Vig RG, Brundo GC. The kinetics of anterior tooth display. *J Prosthet Dent* 1978;39:502–504.
8. Tjan AH, Miller GD, The JG. Some esthetic factors in a smile. *J Prosthet Dent* 1984;51:24–28.
9. Goodacre CJ, Campagni WV, Aquilino SA. Tooth preparations for complete crowns: An art form based on scientific principles. *J Prosthet Dent* 2001;85:363–376.

10. Ward DH. Proportional smile design using the recurring esthetic dental (red) proportion. *Dent Clin North Am* 2001;45:143–154.
11. Rosenstiel SF, Rashid RG. Public preferences for anterior tooth variations: A web-based study. *J Esthet Restor Dent* 2002;14:97–106.
12. Takei H, Yamada H, Hau T. Maxillary anterior esthetics. Preservation of the interdental papilla. *Dent Clin North Am* 1989;33:263–273.
13. Takei HH. The interdental space. *Dent Clin North Am* 1980;24:169–176.
14. LaVacca MI, Tarnow DP, Cisneros GJ. Interdental papilla length and the perception of aesthetics. *Pract Proced Aesthet Dent* 2005;17:405–412.
15. Chu SJ. Range and mean distribution frequency of individual tooth width of the maxillary anterior dentition. *Pract Proced Aesthet Dent* 2007;19:209–215.
16. Prato GP, Rotundo R, Cortellini P, Tinti C, Azzi R. Interdental papilla management: A review and classification of the therapeutic approaches. *Int J Periodontics Restorative Dent* 2004;24:246–255.
17. Spear FM. Maintenance of the interdental papilla following anterior tooth removal. *Pract Periodontics Aesthet Dent* 1999;11:21–28.
18. Priest GF. The esthetic challenge of adjacent implants. *J Oral Maxillofac Surg* 2007;65(7 suppl 1):2–12.
19. Murphy KG. Interproximal tissue maintenance in GTR procedures: Description of a surgical technique and 1-year reentry results. *Int J Periodontics Restorative Dent* 1996;16:463–477.
20. Salama H, Salama MA, Garber D, Adar P. The interproximal height of bone: A guidepost to predictable aesthetic strategies and soft tissue contours in anterior tooth replacement. *Pract Periodontics Aesthet Dent* 1998;10:1131–1141.
21. Tarnow DP, Magner AW, Fletcher P. The effect of the distance from the contact point to the crest of bone on the presence or absence of the interproximal dental papilla. *J Periodontol* 1992;63:995–996.
22. Cho HS, Jang HS, Kim DK, et al. The effects of interproximal distance between roots on the existence of interdental papillae according to the distance from the contact point to the alveolar crest. *J Periodontol* 2006;77:1651–1657.
23. Martegani P, Silvestri M, Mascarello F, et al. Morphometric study of the interproximal unit in the esthetic region to correlate anatomic variables affecting the aspect of soft tissue embrasure space. *J Periodontol* 2007;78:2260–2265.
24. Kois JC. Altering gingival levels: The restorative connection. Part I: Biologic variables. *J Esthet Dent* 1994;6:3–9.
25. Becker W, Ochsenbein C, Tibbetts L, Becker BE. Alveolar bone anatomic profiles as measured from dry skulls. Clinical ramifications. *J Clin Periodontol* 1997;24:727–731.
26. van der Velden U. Regeneration of the interdental soft tissues following denudation procedures. *J Clin Periodontol* 1982;9:455–459.